

A Technique of Cone-Beam Computerized Tomography Superimposition in Implant Dentistry

Leonardo Koerich, DDS, MS^{1*}
 André Weissheimer, DDS, MS, PhD²
 Lindsey Eidson Koerich, DDS, MS¹
 Diandra Luz, DDS³
 Janina Golob Deeb, DDS, MS⁴

INTRODUCTION

The use of cone-beam computerized tomography (CBCT) in implantology has the advantage of allowing the visualization of structures without overlap, and therefore, it provides a closer replication of the anatomic truth.¹ Moreover, it enables a better comparison of the outcomes when scans are taken of the same area before and after the procedure. However, to more accurately compare such images, a reliable method of superimposition is needed. In the fields of oral and maxillofacial surgery and orthodontics, the techniques of accurate superimposition have been studied and extensively validated.²⁻⁵ However, these techniques require the inclusion of the cranial base in the CBCT scan and therefore result in a large field of view (FOV) when assessing changes in the maxilla or the mandible, as well as involve a relatively large amount of radiation for the patient. In implantology, the area being evaluated is often smaller, requiring a different type of superimposition technique.

The use of 2 or more CBCT scans from the same patient taken at different time points for assessment of the outcomes of alveolar ridge augmentation has been published in several studies.⁶⁻¹⁰ However, the only study that presented a reliable method of superimposition was based on the voxel-based technique, which requires a large FOV and exposed the patient to a large amount of radiation.⁹ Recently, Koerich et al¹¹ presented a method to superimpose the maxilla or mandible in nongrowing patients using a medium FOV. This new method can be helpful in comparing differences between the scans obtained at different treatment points while minimizing the exposure to radiation for the patient.

The aim of this report is to describe the application of this step-by-step, voxel-based superimposition technique in implantology and illustrate its use in a case series.

METHOD OF SUPERIMPOSITION

The DICOM (Digital Imaging and Communications in Medicine) files of time point 1 (T1) and time point 2 (T2) are imported into

the software OnDemand 3D v1.0.10.5261 (Cybermed Inc, Seoul, Korea). Both files are loaded at the same time using the "fusion module."

After selecting "manual registration," T2 is moved as close as possible to T1 in the axial, coronal, and sagittal slices. When one clicks on "auto registration," T2 is automatically superimposed onto the T1 image. T2 with the new orientation is then exported by selecting "reslicing" and exporting the "secondary image" only. Once all the previous steps are done, T2 has a new orientation that matches T1 and has the same common coordinates. Both images can be visualized simultaneously using the fusion module of the software.

CASE SERIES

Case 1: Vertical sinus augmentation

A 49-year-old man with no significant medical history presented for placement of a bone graft and implants. Clinical and radiographic examination showed inadequate bone volume for implant placement in the upper left first molar site due to a mesially tipped upper left second molar (Figure 1). The patient was referred for orthodontic treatment to open the space in the upper left first molar area for a bone graft and implant placement and to achieve ideal occlusion and function. The maxillary left second molar was fully uprighted after 12 months of orthodontic treatment, and the first molar space was suitable for an implant-supported restoration (Figure 1b). The implant site was further developed by elevating the floor of the sinus via a lateral window technique. Following completion of bone graft maturation, the CBCT scan showed adequate volume in the implant site as well as favorable root orientation of the adjacent teeth (Figure 1b). The superimposition of the CBCT scans is shown in Figure 1c.

Case 2: Horizontal alveolar ridge augmentation

A 30-year-old man with no significant medical history presented for placement of 3 implants in the left posterior mandible. Following the clinical examination, a CBCT image confirmed a horizontally deficient bone volume incompatible with placement of implants without prior site development. The patient underwent a horizontal ridge augmentation

¹ Private practice, Charlotte, NC.

² University of Southern California, Los Angeles, Calif.

³ Private practice, Porto Alegre, Brazil.

⁴ Virginia Commonwealth University, Richmond, Va.

* Corresponding author, e-mail: lkoerich@gmail.com

DOI: 10.1563/aaid-joi-D-17-00282

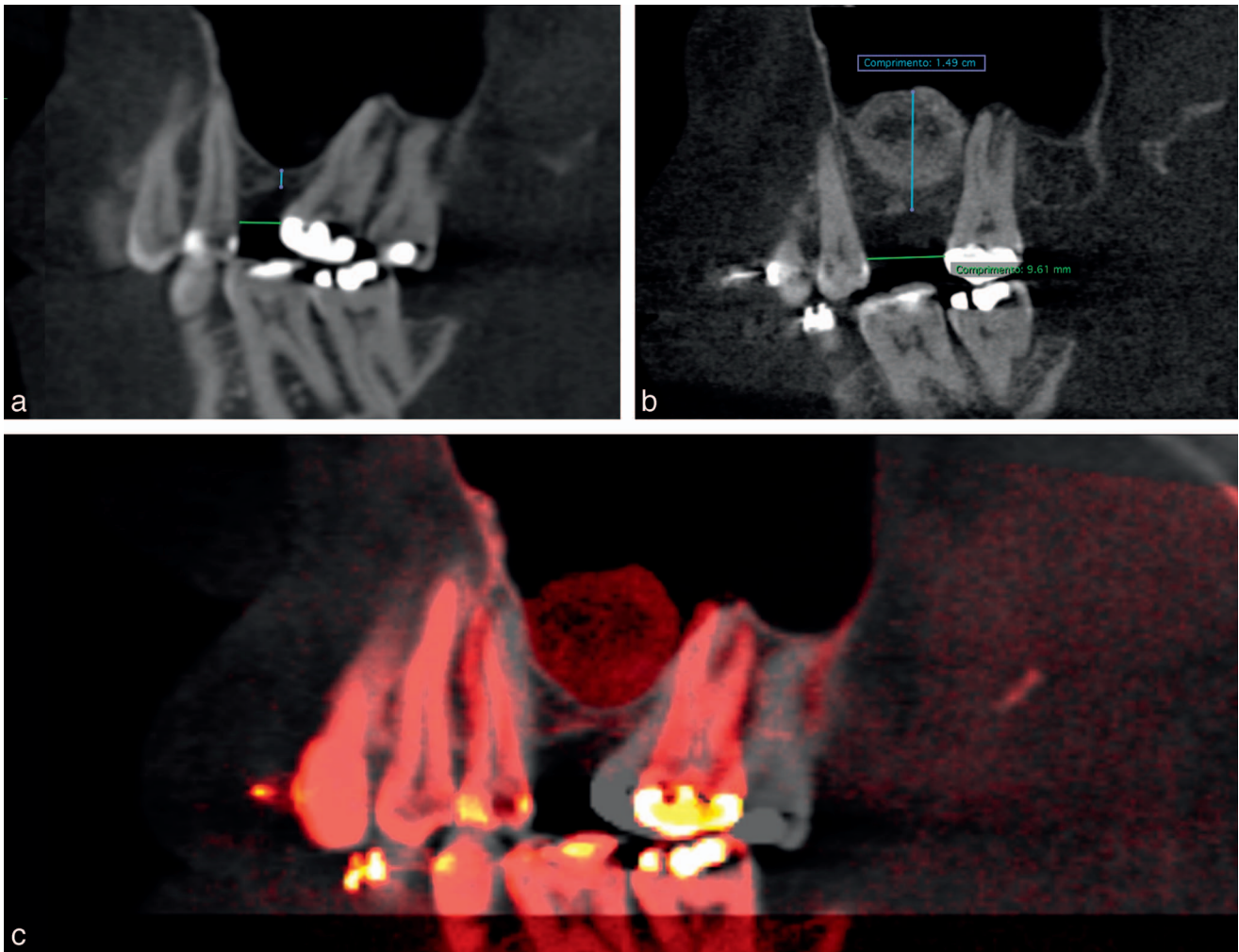


FIGURE 1. (a) Before orthodontic treatment. (b) After orthodontic treatment and graft placement before implant placement. (c) Superimposition of T1 (gray) and T2 (red) showing the movement of the root of No. 13, the upright of No. 15, and the grafted area.

procedure using tenting screws and a bone graft composed of an allograft and xenograft mixed with the patient's own platelet-rich plasma and covered with a collagen membrane. Following a favorable healing period of 6 months, adequate

bone volume for implant placement was observed on a new CBCT. To accurately and objectively assess the gain in bone volume, a superimposition analysis was made using OnDemand 3D software (Figure 2).

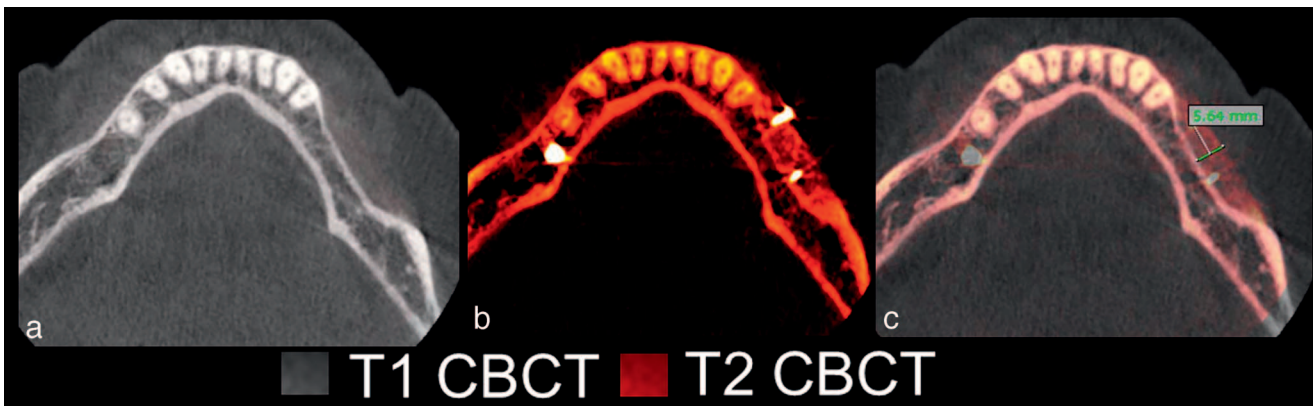


FIGURE 2. (a) T1 axial slice presurgery showing resorbed ridge. (b) T2 axial slice after horizontal bone graft. (c) T1 (gray) and T2 (red) axial slices superimposed showing the amount of bone gained after surgery. Because superimposition was done, the slices being compared are exactly the same. CBCT indicates cone-beam computerized tomography.

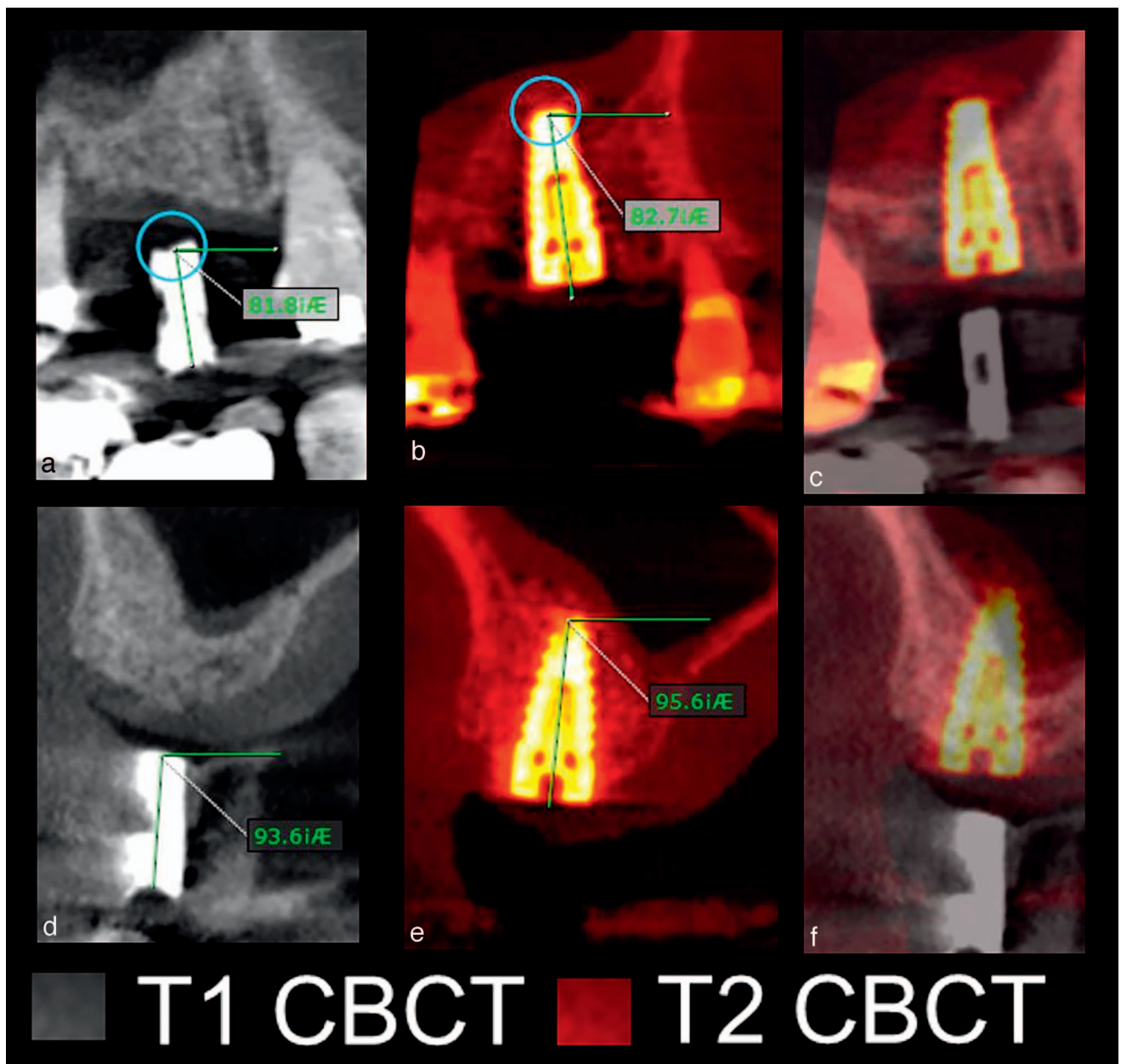


FIGURE 3. (a) T1 sagittal slice showing implant guide angulation. (b) T2 sagittal slice showing implant angulation. (c) T1 (gray) and T2 (red) slices superimposed showing the angulation of the planned treatment and final outcome. (d) T1 coronal slice showing implant guide angulation. (e) T2 coronal slice showing implant angulation. (f) T1 (gray) and T2 (red) slices superimposed showing the angulation of the planned treatment and final outcome. All the slices have the same orientation. CBCT indicates cone-beam computerized tomography.

Case 3: Vertical/crestal sinus floor elevation

A 67-year-old woman presented for placement of an implant in the maxillary right first molar region. On the CBCT, the site showed insufficient ridge height for implant placement.

The patient therefore underwent implant placement surgery with simultaneous vertical sinus augmentation. Elevation of the sinus membrane was achieved using the hydraulic pressure sinus lift technique. An osseous allograft was placed through the osteotomy into the space created on the sinus floor, and a 4.6- × 10.5-mm implant was placed. A

postoperative CBCT was taken of the area to assess the gained bone volume surrounding the implant and to compare the angulation of the implant with the implant guide (Figure 3).

Discussion

This report describes a technique of superimposition of CBCT scans for either clinical or research purposes. The clinical cases presented used 2 scans taken of the area of interest in different

phases of treatment. In more complex treatment scenarios, more than 2 scans can be superimposed provided the reference points remain unchanged. The method error of this voxel-based superimposition for nongrowing patients is very small, while the reproducibility by different examiners is almost perfect.¹¹ Great interexaminer reproducibility could facilitate unbiased comparison between studies by different researchers and prove useful in future studies.

The CBCT machines used in this report included i-Cat (Imaging Sciences International, Hatfield, Penn) for case 1 and Kodak Carestream 9300 (Carestream Health Inc, Rochester, NY) for cases 2 and 3. The machine used does not affect the quality of the superimposition, which has been confirmed by other studies that used KaVo CT (KaVo, Co, Biberach, Germany) and Cranex (Soredex, Tuusula, Finland) machines.^{3,9}

The guidelines by the American Academy of Maxillofacial Radiology proposed that CBCT is the cross-sectional modality of choice for implant site assessment.¹² Given the proper indications, CBCT can be very useful in helping to plan treatment, evaluate treatment outcomes, and assess complications involving implant placement.¹³ A significant increase in the use of CBCT to plan implant placement has been noted between 2008 and 2010, with studies reporting a tendency to use a smaller FOV of 4×4 or 6×6 inches.¹⁴ In cases in which vertical bone in the posterior maxilla is inadequate for implant placement (cases 1 and 3), adequate bone height can be obtained with elevation of the sinus floor by either lateral or vertical approach.¹⁵⁻¹⁷ While the lateral window technique provides good visualization of the grafted area, the vertical augmentation is performed through a small crestal osteotomy and does not allow direct visualization of bone volume gains. An immediate postoperative CBCT and superimposition can provide accurate detail of the newly grafted area.

The method presented in this report can be done very quickly, and the software is user friendly. Once the images are imported, the process to superimpose the scans takes 30 to 40 seconds if cropping of the image is not necessary. When cropping is needed, as in cases where only the mandible needs to be superimposed but the FOV is large, extra steps are required. The length of the superimposition is dependent on the voxel size and computer capacity. Smaller voxel size requires more computer capacity or more time to be processed. When vertebrae are included on the scan, it is advisable to remove them to facilitate the superimposition. As this technique is suitable for scanning of small anatomic areas, it is also applicable in the field of periodontics when small regions undergo comprehensive treatment phases and segmental CBCT scans are indicated to follow the "low as reasonably achievable" principle to limit the amount of radiation to the patient.

CONCLUSION

The superimposition method presented is fast and reliable and has the potential to become the gold standard for objective and reproducible evaluation of anatomic changes in longitudinal implant studies.

ABBREVIATIONS

CBCT: cone-beam computerized tomography
FOV: field of view
T1: time point 1
T2: time point 2

NOTE

The authors have no financial interest in this article nor any product used in this article.

ACKNOWLEDGMENT

The authors would like to thank Dr Daniel Laskin for critical review of the manuscript.

REFERENCES

- Quintero JC, Trosien A, Hatcher D, Kapila S. Craniofacial imaging in orthodontics: historical perspective, current status, and future developments. *Angle Orthod.* 1999;69:491-506.
- Almukhtar A, Ju X, Khambay B, McDonald J, Ayoub A. Comparison of the accuracy of voxel based registration and surface based registration for 3D assessment of surgical change following orthognathic surgery. *PLoS One.* 2014;9:e93402.
- Lee JH, Kim MJ, Kim SM, Kwon OH, Kim YK. The 3D CT superimposition method using image fusion based on the maximum mutual information algorithm for the assessment of oral and maxillofacial surgery treatment results. *Oral Surg Oral Med Oral Pathol Oral Radiol.* 2012;114:167-174.
- Nada RM, Maal TJ, Breuning KH, Berge SJ, Mostafa YA, Kuijpers-Jagtman AM. Accuracy and reproducibility of voxel based superimposition of cone beam computed tomography models on the anterior cranial base and the zygomatic arches. *PLoS One.* 2011;6:e16520.
- Weissheimer A, Menezes LM, Koerich L, Pham J, Cevidanes LH. Fast three-dimensional superimposition of cone beam computed tomography for orthopaedics and orthognathic surgery evaluation. *Int J Oral Maxillofac Surg.* 2015;44:1188-1196.
- Castagna L, Polido WD, Soares LG, Tinoco EM. Tomographic evaluation of iliac crest bone grafting and the use of immediate temporary implants to the atrophic maxilla. *Int J Oral Maxillofac Surg.* 2013;42:1067-1072.
- Diez GF, Fontao FN, Bassi AP, Gama JC, Claudino M. Tomographic follow-up of bone regeneration after bone block harvesting from the mandibular ramus. *Int J Oral Maxillofac Surg.* 2014;43:335-340.
- Lin GH, Salemi JD, Kozloff KM, Chan HL, Wang HL. Measure bone volume and density changes of sites grafted with bone allografts and a titanium mesh on cone-beam computed tomography: a technique. *Implant Dent.* 2015;24:362-366.
- Meloni SM, Tallarico M, Lolli FM, Deledda A, Pisano M, Jovanovic SA. Postextraction socket preservation using epithelial connective tissue graft vs porcine collagen matrix: 1-year results of a randomised controlled trial. *Eur J Oral Implantol.* 2015;8:39-48.
- Ribeiro Filho SA, Francischone CE, de Oliveira JC, Ribeiro LZ, do Prado FZ, Sotto-Maior BS. Bone augmentation of the atrophic anterior maxilla for dental implants using rhBMP-2 and titanium mesh: histological and tomographic analysis. *Int J Oral Maxillofac Surg.* 2015;44:1492-1498.
- Koerich L, Burns D, Weissheimer A, Claus JD. Three-dimensional maxillary and mandibular regional superimposition using cone beam computed tomography: a validation study. *Int J Oral Maxillofac Surg.* 2016;45:662-669.
- Tyndall DA, Price JB, Tetradis S, et al. Position statement of the American Academy of Oral and Maxillofacial Radiology on selection criteria for the use of radiology in dental implantology with emphasis on cone beam computed tomography. *Oral Surg Oral Med Oral Pathol Oral Radiol.* 2012;113:817-826.

13. Klokkevold PR. Cone beam computed tomography for the dental implant patient. *J Calif Dent Assoc.* 2015;43:521–530.
14. Bornstein MM, Brugger OE, Janner SF, et al. Indications and frequency for the use of cone beam computed tomography for implant treatment planning in a specialty clinic. *Int J Oral Maxillofac Implants.* 2015;30:1076–1083.
15. Misch CE. Maxillary sinus augmentation for endosteal implants: organized alternative treatment plans. *Int J Oral Implantol.* 1987;4:49–58.
16. Raja SV. Management of the posterior maxilla with sinus lift: review of techniques. *J Oral Maxillofac Surg.* 2009;67:1730–1734.
17. Summers RB. A new concept in maxillary implant surgery: the osteotome technique. *Compendium.* 1994;15:152, 154–156.